

OUTCOME FOLLOWING ORBITAL FLOOR FRACTURE RECONSTRUCTION USING SILASTIC IMPLANTS

*Sarawin Sakarin**, *Sophilak Sringkarawat**, *Sukhum Tasanachaikul***, *Nuttadon Wongprakob****, *Nutthapong Wanichjaroen****, *Chatchai Pruksapong****, *Akaradech Attainsee****, *Suttisan Jankajorn****, *Chairat Burusapat****

***Division of Plastic and Reconstructive Surgery, Department of Surgery, Songkhla-nakarin Hospital, Songkhla Province, Thailand**

****Department of Emergency Medicine, Phramongkutklo Hospital, Bangkok, Thailand**

*****Division of Plastic and Reconstructive Surgery, Department of Surgery, Phramongkutklo Hospital and Phramongkutklo College of Medicine, Bangkok, Thailand**

Abstract

Background: Orbital floor fracture is typically present with peri-orbital ecchymosis, subconjunctival hemorrhage, enophthalmos and diplopia. The goals of reconstruction are to restore the volume and shape of the orbital cavity with autogenous or alloplastic materials. However, no gold standard exists for orbital implants to treat orbital floor fractures and remains controversial. Silicone was one of the most common biocompatible materials used for orbital floor reconstruction.

Objective: The study aimed to evaluate the outcomes of patients reconstructed using silastic sheets in the case of orbital wall fractures.

Methods: A multi-center, retrospective study of patients with orbital floor fractures was conducted from January 2010 to December 2019. Inclusion criteria included patients with orbital floor fractures and reconstruction using silastic sheets. Patients with orbital floor fractures and treated with other materials were excluded. The database included age, sex, cause of injury, size of floor defects, associated injury, underlying complication and period of follow-up.

Results: A total of 32 patients with orbital floor fractures divided in 20 patients from Phramongkutklo Hospital and 12 patients from Songkla Hospital were included. Twenty-five patients were male (78.13%). Mean age of patients was 35.62 years (range, 15 to 62 years). Causes of injury included traffic accident (78.13%) and body assault (18.75 %). Pure orbital floor fractures were found at 31.25%. Associated injuries included fractured zygoma 43.75%, nasal bone 21.87% and fractured maxilla 12.50%. Average size of defects was 2.01 cm². Average time to follow-up was 2.69 years. Complications were found in three cases (extrusion of silicone sheet, loss of sensation and dystopia). Extrusion was found 2 months postoperation and removal of silicone sheet was performed. Complete recovery of sensation of the infra-orbital nerve was shown at 6 months postoperation.

Conclusion: No gold standard exists for implants to treat orbital floor fractures. Orbital floor reconstruction using silastic sheets involves a low complication rate and satisfactory outcome. Herein, silastic sheets can be safely used for orbital wall augmentation and provides good long term outcomes.

Keywords: Orbital floor fracture, Reconstruction, Silastic sheets

J Southeast Asian Med Res 2020; 4(2): 53-58

<http://www.jseamed.org>

Correspondence to:

Burusapat C, Division of Plastic and Reconstructive Surgery, Department of Surgery, Phramongkutklo Hospital, 315 Ratchawithi Road, Ratchathewi, Bangkok, 10400, Thailand

E-mail: pataranat@hotmail.com

Received: 24 August 2020 Revised: 06 November 2020 Accepted: 01 December 2020

Introduction

Orbital floor fractures are common results of varying velocity and blunt facial trauma. They are typically caused by motor vehicle accident and assault with each being more common in differing demographic settings. They can occur as isolated orbital floor fractures or combined complex fractures involving other facial bones. Orbital trauma is a frequent cause of damage to both bony, soft tissue and neurovascular structures in the surrounding region. Injury patterns can be isolated to the bony orbit or part of a much larger zygomaticomaxillary complex (ZMC), or panfacial fracture patterns.⁽¹⁾ Patients typically present with peri-orbital ecchymosis, subconjunctival hemorrhage, enophthalmos and diplopia.

The goals of orbital reconstruction are to restore the orbital volume and shape of the orbital cavity with autogenous or alloplastic materials.^(2, 3) Complications after orbital reconstruction may occur including infection, hematoma, nerve injury, diplopia, extra-ocular muscle limitation, enophthalmos and sensory change.⁽²⁻⁴⁾

Surgery is only the mainstay treatment, and several materials are suitable for orbital implants ranging from autogenous grafting to alloplastic implants. The most commonly used implants include bone, cartilage, porous polyethylene implants, titanium, poly L-lactide (PLLA) and polydioxanone (PDS).^(1, 5, 6) However, no gold standard exists for orbital implants to treat orbital floor fractures and remains controversial. Silicone was one of the most common biocompatible materials used for orbital floor reconstruction.

Silastic or silicone sheet implants are often used to reconstruct orbital fractures because they are extremely cheap and seem to cause relatively few complications.⁽²⁾ The advantages of silastic sheets include no resorption, short operative time and less tissue reaction. The disadvantages are infection, extrusion and implant displacement.

Silastic sheets are the main implant in Phramongkutklao Hospital and Songkhla Hospital in constructing the orbital floor but a study of long term outcome has never been conducted. This study aimed to evaluate the outcomes and complication rates of patients reconstructed using silastic sheets in the case of orbital wall fractures.

Methods

With the approval of the ethics committee and institutional review board of Phramongkutklao Hospital and following the Helsinki declaration, this multi-center, retrospective study of patients with orbital floor fractures was conducted in Phramongkutklao Hospital and Songkhla-nakarin Hospital from January 2010 to December 2019. Sample size was calculated using calculation PS Software (Power and Sample Size Calculation) Version 2.1. Inclusion criteria included patients with fractures of the orbital floor and treatment using silastic sheet. Patients with orbital floor fractures treated with other material or combined using silastic sheet were excluded. Data information included age, sex, cause of injury, size of floor defects, associated injury, underlying complication, period of follow-up, height, weight, blood pressure, demographics and level of injury. Analyses included descriptive statistics using SPSS for Windows, Version 21.0 (SPSS Inc., Chicago, IL, USA). Categorical variables were presented as number and percentage.

Results

A total of 32 patients with orbital floor fractures divided in 20 patients from Phramongkutklao Hospital and 12 patients from Songkhla Hospital were included in this study (Table 1-3). Twenty-five patients were male (78.13%), and mean age of patients was 35.62 years (range, 15 to 62 years). Causes of injury included traffic accident (78.13%), body assault (18.75 %) and falls from height (3.12 %). All patients were followed-up at least 12 months. Pure orbital floor fractures were found at 31.25%. Associated injuries included fractured zygoma 43.75%, fractured nasal bone 21.87%, fractured maxilla 12.50%, fractured mandible 9.37% and fractured frontal sinus 3.12%.

Average size of defects was 2.01 cm² and average time to follow-up was 2.69 years. Complications were found in three cases (extrusion of silicone sheet, loss of sensation and dystopia). Extrusion was found two months postoperation and silicone sheet was removed. Completed recovery of sensation of the infra-orbital nerve showed six months postoperation. **Figures 1-5** illustrate some of these patients with orbital floor fractures.

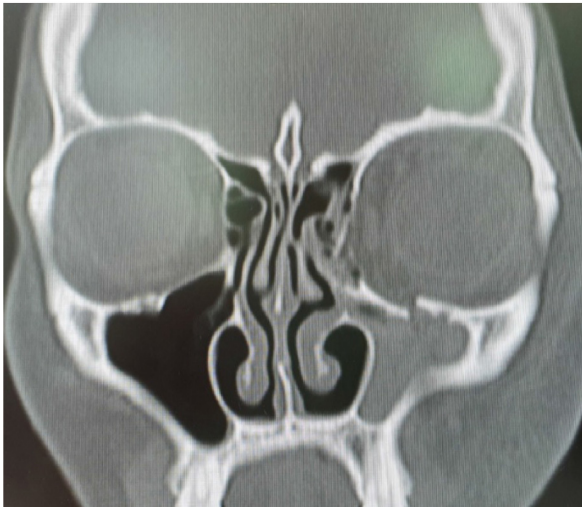


Figure 1. Computed tomography scan of facial bone showing isolated left orbital floor fracture

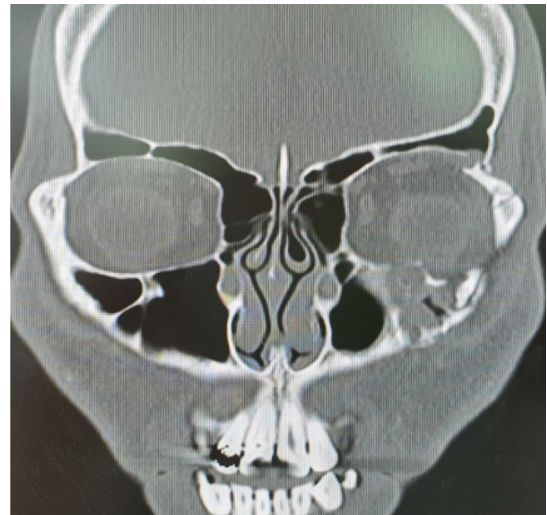

Figure 2. Computed tomography scan of facial bone showing combined fracture left orbital floor and zygoma

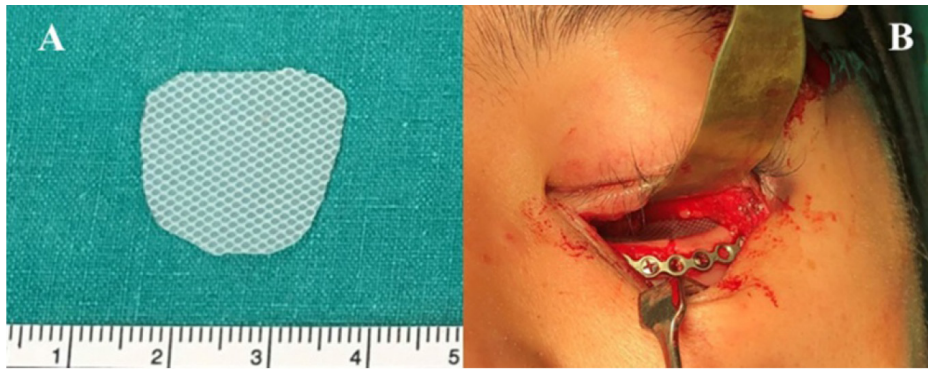


Figure 3. A) demonstrated silastic sheet B) Intra-operative view of corrected floor orbit with silastic sheet

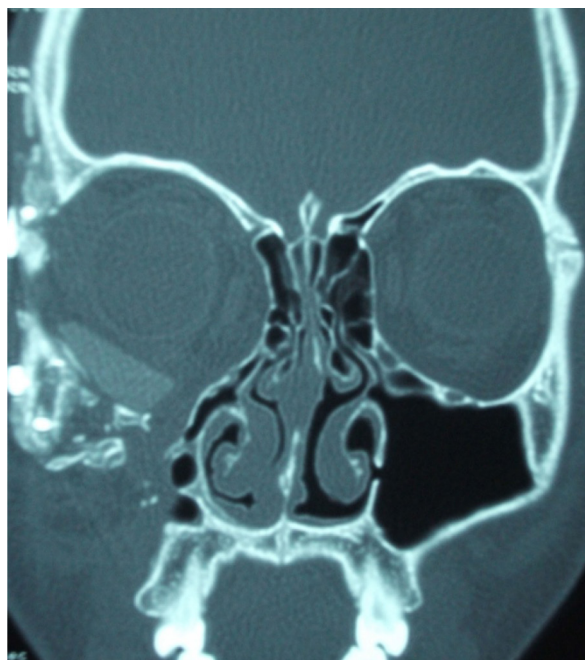

Figure 4. Computed tomography scan of facial bone demonstrated silastic sheet at right orbital floor

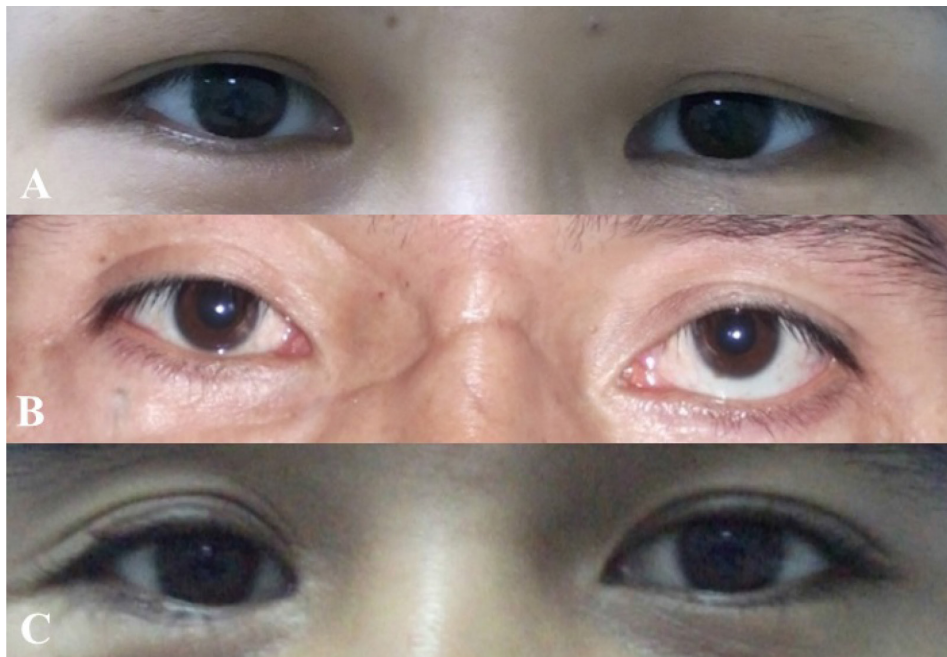


Figure 5. A) A 30-year-old female presented with fracture left orbital floor and corrected with silicone sheet. She was followed up 4 years without any complications. B) A 48-year-old male presented with combined fracture left orbital floor and Lefort II. He was followed up 4 years without any complications. C) A 22-year-old male presented with combined fracture right orbital floor, zygoma and Lefort II. One year follow-up showed mild dystopia on his right eye. Images were obtained with permission.

Discussion

Orbital floor fractures are a result of varying velocity and blunt facial trauma. They are often complex fractures involving other facial bones. They are most common in the male population between the ages of 20 and 40. Pure orbital floor fractures or blowout fractures occur through force transmission from the more rigid infra-orbital rim to the relatively weak orbital floor, known as the “buckling” theory.⁽⁷⁾ Globe-directed trauma results in blowout fractures. Hydraulic theory states that hydraulic pressure from the globe is transmitted to the bony orbit, resulting in fracture of the thin orbital floor.^(7, 8)

Despite extensive literature regarding orbital floor reconstruction, controversy still exists. Surgical indications, timing of surgery and preferred implant materials remain unclear. Most surgeons agree that strong surgical indications include enophthalmos greater than 2 mm during the first weeks, significant hypoglobus, mechanical entrapment, diplopia, and large orbital floor defect ($>1 \text{ cm}^2$).^(2, 9, 10) The aim of the surgery should be to restore the orbital volume to its premorbid condition, and to achieve this, an implant is often required.

Currently a wide array of implants are available to choose from including silastic, titanium, porous polyethylene, resorbable implants as well as autologous bone or cartilage. Teflon and silicone implants have been used since 1963.⁽¹¹⁾ They are considered to be valuable materials used in diverse surgical applications. However, some surgeons prefer using autogenous materials such as iliac or maxillary bone graft to avoid complications from alloplastic implants. Some concerns regard complications due to alloplastic implants. Infection, extrusion and implant displacement are the common complications of silastic implants.

As Morrison et al. reported the majority of silastic complications are observed during the early postoperative period and chances of complications decrease with longer asymptomatic periods.⁽¹²⁾ In other words, chances of observing a patient with silastic infection after orbital reconstruction decreases over time. In addition, silastic sheets become difficult to detect by computed tomography scan and magnetic resonance imaging after silicone deterioration. Therefore, diagnosis of silastic complications long after the primary surgery becomes very

difficult for the new physician in charge when not knowing the details of past orbital reconstruction.

Mwanza T-C. K et al. showed satisfactory results regarding late repair of the orbital floor blowout fracture using silastic implant.⁽¹³⁾ Simon J.B. et al. reported that the appropriate use of silastic implants for orbital floor reconstruction showed good results involving low complication rates including an acceptably low rate of infection and extrusion, as well as high patient satisfaction levels.⁽¹⁴⁾ However, Muneo et al. reported a case of chronic infection seen after 28 years of silastic implant used in orbital floor repair.⁽¹⁵⁾

One advantage of orbital floor augmentation with autogenous bone graft is less infection. Disadvantages of orbital floor augmentation include autogenous bone graft were donor site paresthesia bone resorption, postsurgical pain, excessive blood loss and increased operative time. Advantages of orbital floor augmentation using alloplastic comprise no resorption and less operative time. Disadvantages of orbital floor augmentation with alloplastic include extrusion and infection.

A recent systematic review, evaluating materials for orbital floor reconstruction, found no conclusive evidence to suggest one material was better than another; rather, the surgeon must rely on his or her own experiences and the unique characteristics of each material to individualize treatment plans.^(7, 16)

Retrospective study design may have been a limitation of this study; however, data from a multicenter study may increase the reliability of results. From our data, long term complication was at acceptable rate. The results confirmed silastic sheets can be carefully applied in good candidate patients.

Conclusion

No gold standard exists for orbital implants to treat orbital floor fractures and remains controversial. Orbital floor reconstruction using silastic sheets involves a low complication rate and satisfactory outcomes. Herein, silastic sheets can be safely used for orbital wall augmentation and good long term outcomes.

Potential conflicts of interest

The authors declare they have no potential conflicts of interest.

Disclosure

None of the authors have a financial interest in any of the products, devices or drugs mentioned in this article.

Data availability statement

Individual clinical data used to support the findings of this study are available from the corresponding author upon request.

References

1. Lozada KN, Cleveland PW, Smith JE. Orbital Trauma. *Semin Plast Surg* 2019; 33: 106-13.
2. Nam SB, Bae YC, Moon JS, Kang YS. Analysis of the postoperative outcome in 405 cases of orbital fracture using 2 synthetic orbital implants. *Ann Plast Surg* 2006; 56: 263-7.
3. Cole P, Boyd V, Banerji S, Hollier LH Jr. Comprehensive management of orbital fractures. *Plast Reconstr Surg* 2007; 120: 57S-63S.
4. Brucoli M, Arcuri F, Cavenaghi R, Benech A. Analysis of complications after surgical repair of orbital fractures. *J Craniofac Surg* 2011; 22: 1387-90.
5. Park MS, Kim YJ, Kim H, Nam SH, Choi YW. Prevalence of diplopia and extraocular movement limitation according to the location of isolated pure blowout fractures. *Arch Plast Surg* 2012; 39: 204-8.
6. Gunarajah DR, Samman N. Biomaterials for repair of orbital floor blowout fractures: a systematic review. *J Oral Maxillofac Surg* 2013; 71: 550-70.
7. Gart MS, Gosain AK. Evidence-based medicine: Orbital floor fractures. *Plast Reconstr Surg* 2014; 134: 1345-55.
8. Pfeiffer RL. Traumatic Enophthalmos. *Trans Am Ophthalmol Soc* 1943; 41: 293-306.
9. Cruz AA, Eichenberger GC. Epidemiology and management of orbital fractures. *Curr Opin Ophthalmol* 2004; 15: 416-21.
10. Rinna C, Ungari C, Saltarel A, Cassoni A, Reale G. Orbital floor restoration. *J Craniofac Surg* 2005; 16: 968-72.
11. Lipshutz H, Ardizzone RA. The Use of Silicone Rubber in the Immediate Reconstruction of Fractures of the Floor of the Orbit *J Trauma* 1963; 3: 563-68.

12. Morrison AD, Sanderson RC, Moos KF. The use of silastic as an orbital implant for reconstruction of orbital wall defects: review of 311 cases treated over 20 years. *J Oral Maxillofac Surg* 1995; 5: 412-17.
13. Mwanza JC, Ngoy DK, Kayembe DL. Reconstruction of orbital floor blow-out fractures with silicone implant. *Bull Soc Belge Ophtalmol* 2001; 280: 57-61.
14. Prowse SJ, Hold PM, Gilmour RF, Pratap U, Mah E, Kimble FW. Orbital floor reconstruction: a case for silicone. A 12 year experience. *J Plast Reconstr Aesthet Surg* 2010; 63: 1105-09.
15. Miyasaka M, Tanaka R, Hanai U, Yamazaki A, Iida M, Akamatsu T. A Case of chronic infection 28 years after silicone orbital implant. *Tokai J Exp Clin Med* 2008; 33: 35-8.
16. Avashia YJ, Sastry A, Fan KL, Mir HS, Thaller SR. Materials used for reconstruction after orbital floor fracture. *J Craniofac Surg* 2012; 23: 1991-97.